

BRIGITTE ZIMMERLI
FRANZISKA JEGER
ADRIAN LUSSI

Klinik für Zahnerhaltung, Präventiv- und Kinderzahnmedizin, Zahnmedizinische Kliniken, Universität Bern

Corresponding author

Dr. Brigitte Zimmerli, Klinik für Zahnerhaltung, Präventiv- und Kinderzahnmedizin,

Freiburgstrasse 7, 3010 Bern

Tel. +41 31 632 25 80

Fax +41 31 632 98 75

E-mail:

brigitte.zimmerli@zmk.unibe.ch

Schweiz Monatsschr Zahnmed 120: 306–313 (2010)

Accepted for publication:
7 July 2009

Bleaching of Nonvital Teeth

A Clinically Relevant Literature Review

Key words: bleaching, nonvital teeth, walking bleach technique, root resorption

Summary Today, the bleaching of nonvital, discolored teeth is a low-risk routine treatment for improving esthetics. This review article focuses on the etiology of tooth discolorations, different treatment techniques, and risks of bleaching procedures. Some tooth discolorations in endodontically treated teeth are caused by dental treatments. The three most popular techniques for nonvital tooth bleaching are the walking bleach technique, inside/outside bleaching, and in-office bleaching. The walking bleach technique is a relatively reliable, fairly simple technique for dentists and patients. Inside/outside bleaching can be used additionally when internal and external bleaching must be combined. In-office bleaching seems to be a short-term

solution, the effects of which can largely be attributed to dehydration of the teeth. There are still some open questions concerning the bleaching agents. Improved safety seems desirable with regard to adding thiourea as a scavenger of radicals or newer materials such as sodium percarbonate. The thermocatalytic technique, insufficient cervical sealing, and high concentrations of bleaching agents should be avoided, as this can increase the risk of cervical root resorptions. Patients should be informed about the low predictability of bleaching success and the risk of recurrent discoloration. The risk of cervical root resorption should be discussed with the patient. There is a strong correlation between root resorption and dental trauma.

Introduction

Discolored anterior teeth are often perceived as an esthetic detraction. Because of the growing need for beautiful, white teeth and the establishment of esthetic treatment methods, the bleaching of nonvital teeth has become increasingly important in recent years. In the middle of the 19th century, the first attempts were made to lighten discolored teeth using various agents. Initially, oxalic acid was used, until the tooth-bleaching effect of hydrogen peroxide was discovered in 1884 (GOLDSTEIN 1997). The bleaching of nonvital teeth was first mentioned by Garretson in 1895, who used chlorine as the bleaching agent (FASANARO 1992). However, it wasn't until 1951 that hydrogen peroxide was used to bleach nonvital teeth (PEARSON 1951). The bleaching of nonvital teeth is a minimally invasive intervention which, if performed correctly, bears only slight risks.

Nevertheless, contradictory opinions and unanswered questions exist about this method. This paper reviews the current literature, presenting both the causes of discoloration in non-

vital teeth and the treatment options, as well as degrees of success. In addition, focus is placed on possible side effects of these treatment options and the dentist's resulting obligation to thoroughly inform patients.

Materials and Methods

An Internet literature search in PubMed was started (status: January 2009), using the following search words (total hits/number of processed articles in text/articles already covered by previous search words): walking bleach (51/14/0), endodontic bleaching (47/8/4), internal bleaching of teeth (64/10/5), intracoronal tooth bleaching (75/10/5), inside/outside bleaching of teeth (5/3/2), resorption and bleaching (89/20/13), risks and tooth bleaching (51/9/9), endodontics and discolorations (216/20/9) /discolorations (9/2/1), intrinsic tooth discoloration (57/2/1). Only original papers and reviews were evaluated and discussed. Case reports were cited according to their clinical relevance. Abstracts were not included in this paper. A manual search was performed after the original articles had been read.

Tab. Etiology of intrinsic discolorations
(PLOTINO ET AL. 2008).

Pre-eruptive causes	Post-eruptive causes
<ul style="list-style-type: none"> – Medications (Tetracycline) – Metabolism (Fluorosis) – Genetics (hyperbilirubinaemia, Amelogenesis imperfecta, cystic fibrosis of the pancreas) – Dental trauma 	<ul style="list-style-type: none"> – Pulpal necrosis – Intrapulpal hemorrhage – Residual pulp tissue after endodontic treatment – Endodontic materials (medications/irrigants, root canal sealer) – Filling materials – Root resorption – Aging process

References on this topic were processed. Additionally, the articles in PubMed were used in the category “related articles” to complete the article search. Predominantly articles from the last ten years were analyzed, but older studies were cited if they were judged to be currently relevant.

Etiologically intrinsic discolorations

Discolorations can be of extrinsic or intrinsic origin. External discolorations result from the consumption of certain foods, beverages, or tobacco products (or similar), as well as from inadequate oral hygiene or certain oral hygiene products. Moreover, a thinning of the dental enamel during aging also darkens the tooth (WATTS & ADDY 2001). An intrinsic discoloration is defined as one with its origin within the pulp chamber. This includes hemorrhage, necrosis, calcification, and iatrogenic discoloration due to dental treatment (Tab.).

Hemorrhage of the pulp is the most common cause of discoloration after trauma. Blood enters the dentinal tubules and then decomposes. This leads to a deposit of chromogenic blood degradation products, such as hemosiderin, hemine, hematin, and hematoïdin (ARENS 1989). Pulp extirpation also provokes hemorrhaging into dentin (ARENS 1989). In the same manner, pulp necrosis can give rise to chromogenic degradation products. In an in vitro study, teeth were treated with whole blood, erythrocytes, blood plasma with platelets, or saline solution. The strongest discolorations occurred in the group treated with erythrocytes. In all discolored samples, the presence of hematin, hemoglobin, and hemosiderin was histochemically detected (MARIN ET AL. 1997). Aside from blood degradation products, protein degradation products of pulpal tissue are also responsible for discolorations.

The calcification of the pulp causes discoloration through obliteration of the dentinal tubules and buildup of tertiary dentin (WATTS & ADDY 2001), but the tooth remains vital. This process often occurs following trauma. Other factors, such as abrasion, erosion, or iatrogenic irritations can also stimulate the vital pulp to initiate obliteration processes (THORDARSON ET AL. 1991).

A number of dental interventions can cause internal discoloration. If the pulpal tissue is not completely removed during endodontic treatment, the remaining tissue can lead to discoloration (BROWN 1965, FAUNCE 1983). Irrigants, root-canal restorative materials, and other restorative materials can also cause discoloration. Combining irrigants which contain sodium hypochlorite (even at low concentrations) and chlorhexidine leads to brownish-red precipitates (BASRANI ET AL. 2007). In order to prevent this reaction, a separate rinse between the other two must be performed, for instance, with Ringer’s solution or distilled water. A reddish-brown precipitation reaction is also

observed when rinsing with Biopure MTAD® (mixture of tetracycline, citric acid, and detergent) is performed after irrigation with sodium hypochlorite (TAY ET AL. 2006).

The type of root-canal filling material and medication agent play a role in the discoloration tendency of the tooth (VAN DER BURGT & PLESSCHAERT 1985, 1986, VAN DER BURGT ET AL. 1986a, b). Especially products containing tetracycline are prone to discoloring the tooth. A well-known example of this is Ledermix® (KIM ET AL. 2000a, b). Increased discoloration is observed when these products are left in the region of the pulpal cavity (KIM ET AL. 2000a, b). Even calcium hydroxide can lead to discoloration of the dentin during revisions of root-canal fillings. Calcium-hydroxide staining was much more pronounced than when camphormonochlorophenol was used (TINAZ ET AL. 2008).

Depending on the material, discolorations caused by endodontic filling materials are bleachable (VAN DER BURGT & PLESSCHAERT 1986). In an in vitro study, discoloration was found for all the tested root-canal sealers after three, six, and nine months. The tooth discoloration was always most pronounced in the cervical third. Of the tested products, Endofill® demonstrated the greatest discoloration tendency, followed by zinc-oxide eugenol, Tubuliseal®, AH 26®, gutta-percha, Apatite Root Sealer® and Cavizol®. The least discoloration was seen in the control group with distilled water (PARTOVI ET AL. 2006). In that study, these tooth discolorations occurred despite the fact that the sealer did not penetrate into the dentinal tubules. Tooth discoloration following sealer application showed a progression over twelve months in an in vitro trial (PARSONS ET AL. 2001). Although mineral trioxide aggregate (MTA) possesses excellent biocompatibility (RIBEIRO ET AL. 2005, RIBEIRO ET AL. 2006), this gray-colored material leads to undesirable tooth discolorations in the esthetic region of the dentition (BORTOLUZZI ET AL. 2007). A case report exists about discoloration of hard dental tissues after the application of white MTA (JACOBOWITZ & DE LIMA 2008). It is thus assumed that even with white MTA, discoloration occurs due to the iron oxidation process (tetracalcium aluminum ferrite).

Mechanism of bleaching

Discolorations arise due to the formation of chemically stable, chromogenic products. Pigments consist of long-chain organic molecules. In bleaching, these compounds are oxidized: they are split into smaller molecules which are usually lighter. During bleaching, the long-chain organic molecules are transformed into carbon and water, and – together with nascent oxygen – are released.

Some manufacturers recommend the additional application of heat or light. The application of heat in the pulpal cavity must be considered problematic (→ root resorption). The use of a diode laser did not improve the bleaching result compared to light application with a halogen lamp (GONTIJO ET AL. 2008). However, the use of the halogen lamp also produced a marked temperature increase in the root canal, and the bleaching effect was not better than that with the walking bleach technique (CARRASCO ET AL. 2007).

Bleaching agents

Tooth bleaching agents are classified by the Federal Health Office of Switzerland and the Medications Institute Swissmedic as cosmetics. This stipulates that patients can directly acquire products with a maximum of 6% hydrogen peroxide or an equivalent amount of other oxygen-releasing agents. Products with a higher concentration of such agents are approved only for professional use (dentist).

Hydrogen peroxide (H_2O_2) is an effective bleaching agent. Nevertheless, high concentrations ($\geq 30\%$) should only be used with caution, in order to avoid increasing the risk of root resorption (ATTIN ET AL. 2003).

Sodium perborate occurs in the form of mono-, tri- ($NaBO_2 \cdot H_2O_2 \cdot 3H_2O$) or tetrahydrate. Upon adding water, H_2O_2 is released. The bleaching effect is not weakened if sodium perborate is mixed with water instead of hydrogen peroxide (ROTSTEIN ET AL. 1993, ARI & UNGÖR 2002).

Currently, there are very few studies on the use of *sodium percarbonate* ($2Na_2CO_3 \cdot H_2O_2$). This agent was long ignored, as its stability during storage was very poor. Thanks to a coating procedure, this product now stores well and is a marketable bleaching agent. An in vitro study found the bleaching effect of sodium percarbonate (mixed with water) to be similar to that of 30% hydrogen peroxide (KANEKO ET AL. 2000). However, clinical studies are still lacking.

Carbamide peroxide ($CH_4N_2O \cdot H_2O_2$) is an organic compound containing hydrogen peroxide and urea. In an in vitro test, carbamide peroxide showed a bleaching ability equal to that of hydrogen peroxide (LIM ET AL. 2004). Products which contain 10% carbamide peroxide release 3.5% hydrogen (GOLDSTEIN & KIREMIDJIAN-SCHUMACHER 1993).

Indications for internal bleaching

All discolorations which arise due to metal ions (silver pins, amalgam fillings) are not reliably bleachable with today's methods (PLOTINO ET AL. 2008).

In contrast, all other discolorations can be removed, often with remarkable results (Figs. 1, 2). Today, clinical practice has taught us that a satisfactory color change can be brought about by a maximum of three applications of bleaching agent.

A sealed root-canal filling is an important requirement for allowing an endodontically treated tooth to be bleached. The tooth must be symptom-free, but a waiting period is called for in the case of a radiologically detectable periapical radiolucency. Such lesions should be observed to determine whether the alteration is increasing or if a healing process is apparent. In every case, the root-canal filling material should be sealed with a base material, in order to prevent penetration of the bleaching agent into the periodontal space or root canal (DE OLIVEIRA ET AL. 2003). The ubiquitous cements used to close perforations must also be covered with a base. Particularly MTA exhibits a much-reduced marginal seal when it comes into contact with bleaching agents (LOXLEY ET AL. 2003). Prior to

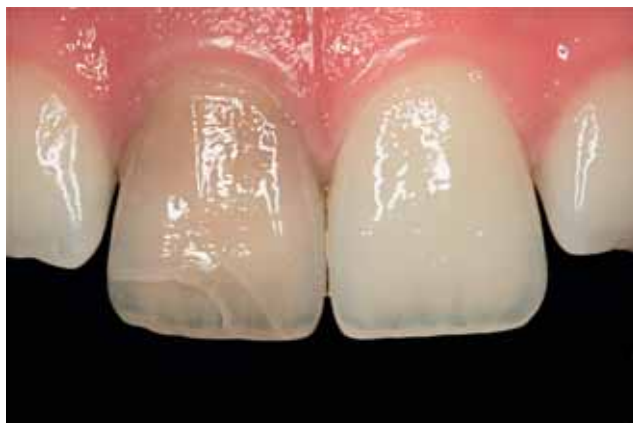

Fig. 1 Young patient after anterior tooth trauma and endodontic treatment of tooth 11 five years ago alio loco.

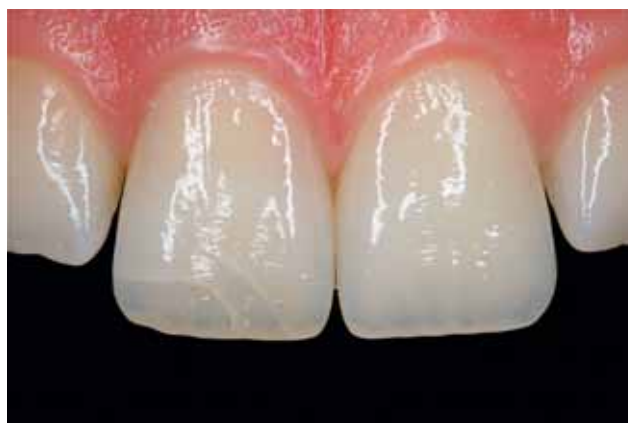


Fig. 2 Status after the walking bleach technique with three applications of 35% hydrogen peroxide (Opalescence Endo, Ultradent).

bleaching, insufficient coronal restorations must be replaced by restorations providing an excellent marginal seal.

Root resorptions

Where the remaining dentin walls are very thin, it is recommended that only low concentrations of bleaching agent be applied, or that sodium perborate be mixed with distilled water, in order to effect the bleaching of the tooth (DIETSCHI 2006). This is intended to prevent the bleaching agent from entering the periodontal space through the ubiquitous micro-perforations and there causing inflammation which can facilitate root resorption. The etiology of root resorptions has yet to be comprehensively explained. The incidence mentioned in the literature varies greatly, from 1% to 13% (HARRINGTON & NATKIN 1979, LADO ET AL. 1983, CVEK & LINDWALL 1985, LATCHAM 1986, 1991, HEITERSAY ET AL. 1994). The general recommendation today is not to heat the bleaching agent in the access cavity and thus forego its thermocatalytic activation, because heat can damage periodontal tissue and lead to an increased resorption rate at the root surface (FRIEDMAN 1997, ATTIN ET AL. 2003). Furthermore, a marked increase in hydrogen peroxide on the tooth's exterior surface has been measured when the bleaching agent is heated in the pulp cavity (DAHLSTROM ET AL. 1997, FARMER ET AL. 2006). It is advantageous to cover the root-canal filling material with a base in order to prevent resorptions. The importance of this cervical sealing has been extensively documented. For instance, no root resorptions were observed over a 20-year period in a practice where 30% hydrogen peroxide was used with correct cervical sealing (DIETSCHI 2006). However, as a case report, this outcome must be viewed critically. Cervical resorptions can occur more frequently with higher concentrations of bleaching agent, past trauma, and the application of heat (thermocatalytic method) (HEITERSAY ET AL. 1994, FRIEDMAN 1997, ATTIN ET AL. 2003). Studies in Australia, in which bleaching was performed with 30% hydrogen peroxide and heat application, found that 2% of all teeth followed up exhibited cervical resorptions. In all cases of resorption, a prior tooth trauma had occurred (HEITERSAY ET AL. 1994). In examinations of cervical root resorption, it was shown that orthodontic treatment is responsible for the majority of cervical resorptions (24.1%), with tooth trauma being the second most common predisposing factor for cervical resorptions (15.1%) (HEITERSAY 1999). Defects at the cemento-enamel junction increase the penetration of bleaching agent into the periodontal space (ROTSTEIN ET AL. 1991a). There is no case report documenting cervical resorption after vital tooth

bleaching. By adding thiocarbamide (radical scavenger) to hydrogen peroxide, the amount of hydrogen peroxide penetrating through the dentinal tubules was greatly reduced (FARMER ET AL. 2006).

Recurrence

The recurrence rate in bleached, endodontically treated teeth is relatively high, and the mechanism has not been completely elucidated. Depending on the study, the reported recurrence rate after two years is 10%, after five years 25%, and after eight years 49% (FRIEDMAN 1997, FRIEDMAN ET AL. 1988, HOLMSTRUP ET AL. 1988, GLOCKNER ET AL. 1999). The outcome in another study is sobering: six years after bleaching, a success rate of 45% was documented; the conclusion was drawn that bleaching nonvital teeth does not constitute a long-term solution in the permanent dentition (FEIGLIN 1987). However, that study is relatively old, and bacterial management during bleaching procedures was not adequately performed. Moreover, the fillings were largely placed without the adhesive technique, which led to increased penetration of pigments. It is known that most discoloration of nonvital teeth arises as a result of degradation products of hemoglobin and pulpal tissue (ARENS 1989). Then as now, it is not clear whether the recurrence of discoloration in bleached teeth is caused by the same substances or by penetration of pigments from the oral cavity. Observations from daily practice indicate that bleaching success has largely been modest, or discoloration recurrence happened quickly if the tooth became discolored relatively soon after endodontic treatment (DIETSCHI 2006). In a long-term follow-up of 35 patients, 22 cases (62.9%) presented satisfactory results 16 years after bleaching treatment (combined method: in-office bleaching with subsequent walking bleaching). In 13 patients (37.1%), the result was no longer satisfactory and obvious darkening had taken place. No root resorptions occurred (AMATO ET AL. 2006). In contrast, another study using the same bleaching technique found darkening of up to four shades on the VITA color scale in just under 50% of the 26 bleached teeth (DELIPERI & BARDWELL 2005). In part, dentists judge bleaching success much more critically than do patients. After a 5-year observation period, 75% of the cases were judged as successful by the dentist, while 98% of the patients were satisfied with the results (GLOCKNER ET AL. 1999).

Technique

Prior to bleaching, each case should be photodocumented (Fig. 1), including a color key (Fig. 3), to objectify the result and make treatment success verifiable. The patient must be informed of the risks of the treatment and alternative treatment methods. It is important that the patient be aware that existing restorations may not be bleachable and therefore subsequent costs may arise if the old restorations no longer match the color of the teeth after bleaching (Fig. 4). There is no guarantee that bleaching will be successful. The patient must be asked about the usual allergies to composites, plastics, latex, and peroxide. No bleaching agents may be used in pregnant or lactating women. Careful consideration is also called for with children and adolescents. In every case, the permission of the parent or legal guardian is required, and the child her- or himself must express the desire for bleaching treatment because of suffering from the discoloration of the nonvital tooth. A good cervical seal is decisive in young teeth, as the diffusion rate of the bleaching agent through the tooth is much higher than in older patients (CAMPS ET AL. 2007). Although a case report exists on the bleaching of nonvital deciduous

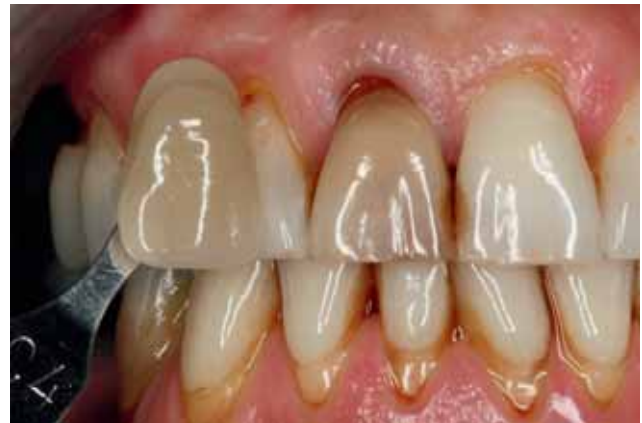

Fig. 3 Baseline situation with Vita color key. Tooth 11 shows greater discoloration than the shade sample Vita C4.

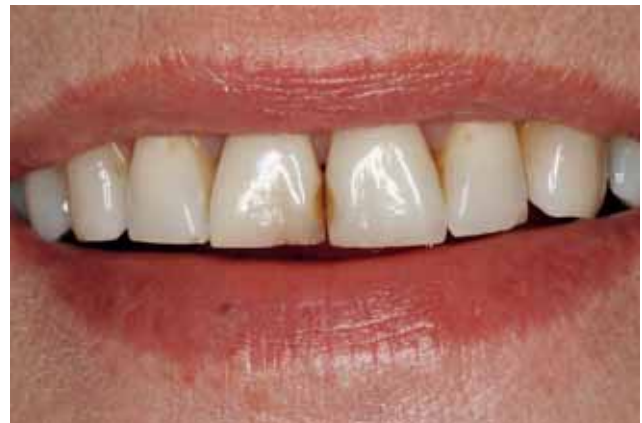

Fig. 4 Final documentation (same patient as in Fig. 3). Bleaching success is satisfactory, but the discolored approximal composite restorations on 11 and 21 are even more obvious.

teeth (BUSSADORI ET AL. 2006), the authors of the article reject this form of treatment due to lack of compliance and a high cost:benefit ratio. This treatment approach does not seem practical. The patient must be informed that by preparing a new access cavity, an increased risk of tooth fractures exists during treatment, and that the tooth to be bleached must not be loaded too heavily (BARATIERI ET AL. 1995).

There are basically three different options for lightening nonvital teeth: the walking bleach, inside/outside bleaching and the in-office bleaching techniques. These three techniques are presented in the following, including clinical procedure, time requirements, and risks.

Walking bleach technique

This bleaching technique was first described by Spasser (SPASSER 1961). Sodium perborate is mixed with water into a paste and then inserted into the access cavity. Later, the technique was modified by mixing sodium perborate with hydrogen peroxide and inserting this into the access cavity (NUTTING & POE 1967). It was subsequently shown that there is no difference in effectiveness between these two methods (HOLMSTRUP ET AL. 1988, ROTSTEIN ET AL. 1991b, ARI & UNCÖR 2002). An improvement was found in vitro when sodium perborate was mixed with carbamide peroxide instead of with distilled water. It made no difference if carbamide peroxide was used in concentrations of 10% or 35% (YUI ET AL. 2008). In the walking bleach tech-

nique, first a tissue-conserving access cavity is made such that the entire pulpal cavity is visible and cleanable (Fig. 5). The root-canal filling material is shortened 2–3 mm subgingivally. This is controlled using a periodontal probe (Fig. 6). An impermeable base is laid on the root-canal filling material (resin-modified glass-ionomer cement [RMGIC], such as Vitrebond®, or conventional GIC). The application of a RMGIC showed a better apical seal than conventional GIC (DE OLIVEIRA ET AL. 2003). The pulpal cavity must be free of root-canal filling material. The bleaching gel is inserted into the tooth and the access cavity is sealed to the outside with a provisional filling. While investigating different provisional filling materials, the question was also asked whether covering the bleaching agent with rubber (small piece of rubber-dam) would additionally improve the sealing of the cavity. The dye penetration test showed no significant difference between the use of a rubber covering and the direct provisional closure. Cavit and Coltosol used as provisional restorative materials were better than Fermit, and this was better than zinc-oxide eugenol and zinc-oxide phosphate cement (HOSOYA ET AL. 2000). Ideally, a provisional adhesive restoration is placed, because this improves the seal against bacterial penetration.

After a few days, the bleaching result is examined and, if needed, bleaching agent is again inserted into the access cavity. A recent study attempted – based on the diffusion rate of hydrogen in dentin – to determine the ideal timepoint for reapplying bleaching agent. Given the different structure of young and old dentin, the researchers determined an ideal applica-

tion time of 33 hours for young patients and 18 hours for older patients (CAMPS ET AL. 2007). After completion of bleaching agent application, the results should be photodocumented, which also serves to evaluate long-term success (Figs. 2, 4, 7 and 8). Instead of sodium perborate, carbamide peroxide or hydrogen peroxide can also be used for the walking bleach technique, using the same procedure described above (VACHON ET AL. 1998). 37% carbamide peroxide shows the best penetration into dentin, while sodium perborate mixed with 20% hydrogen peroxide or 27% carbamide peroxide does not penetrate as deeply into dentin (CARRASCO ET AL. 2003). In another study, in order to improve penetration into dentin, the access cavity was first etched with phosphoric acid so that the dentin tubules were slightly opened. However, this did not improve results, at least with more highly concentrated bleaching agents (CASEY ET AL. 1989). Bleaching success seems largely dependent on the application duration of the bleaching agent. For this reason, this bleaching method often performs better than the in-office technique (DIETSCHI ET AL. 2006). After the desired bleaching result has been obtained or slightly surpassed, sometimes an application of calcium hydroxide is recommended in order to diminish oxygen inhibition of the polymerization of the definitive composite filling, and to counteract the increased permeability of the dentin caused by the bleaching agent (DEMARCO ET AL. 2001) as well as raise the low pH value in the cavity (KEHOE 1987). However, the authors of this article assign little clinical relevance to increasing the pH in this way due to the great buffering capacity of the dentin. The bond strengths

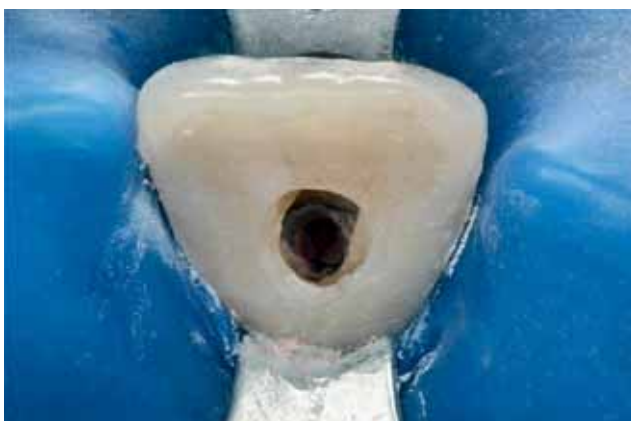

Fig. 5 The access cavity is kept as small as possible. Discolored dentin is not removed. Same case as in Fig. 1.

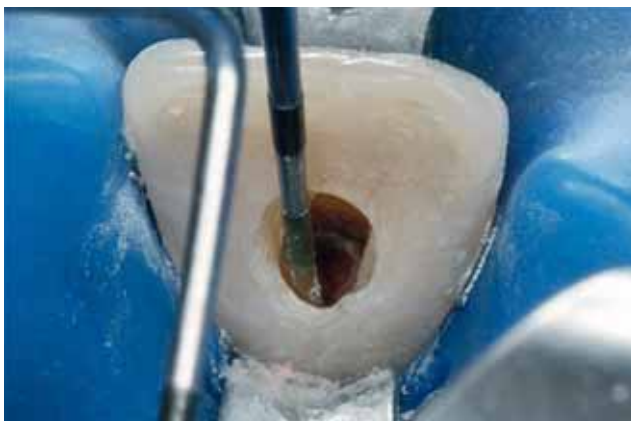


Fig. 6 The root filling material is shortened 2–3 mm subgingivally. The depth of the access cavity is checked with a periodontal probe.

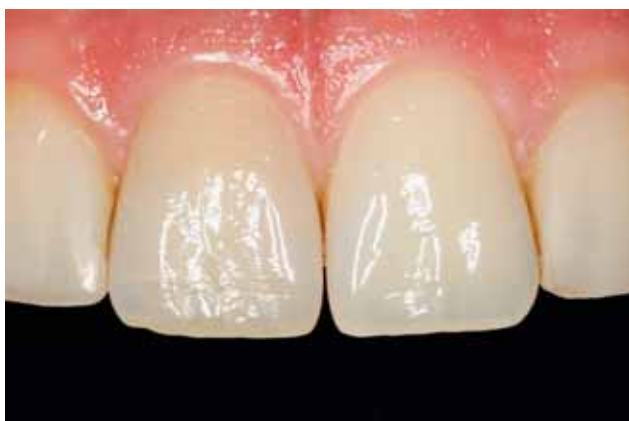

Fig. 7 Follow-up examination nine months after bleaching. During that period, the lateral incisors were widened using composite.

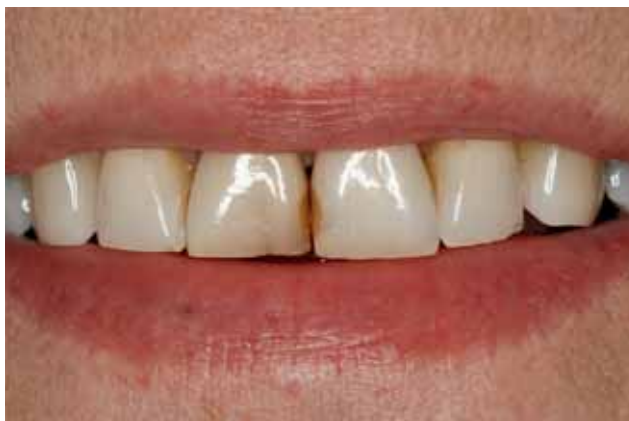

Fig. 8 Follow-up three months after bleaching. The patient did not want new composite restorations.

of adhesive systems to dentin were not found to be negatively influenced by sodium perborate, hydrogen peroxide or carbamide peroxide compared to the unbleached control group (MÜLLER ARCARI ET AL. 2007). This is contrary to other investigations, in which bleaching agents markedly reduced bond strengths (LAI ET AL. 2002). Instead of a waiting interval between bleaching agent application and restoration, an ascorbic acid solution (10%) can be used to promote normal adhesive bond strengths (LAI ET AL. 2002). Additionally, it has been shown that ethanol and acetone in the adhesive systems negate the inhibiting effect of bleaching agent on polymerization (BARGHI & GOLDWIN 1994, SUNG ET AL. 1999).

Hydrogen peroxide (30%) can have a detrimental effect on the microhardness of enamel and dentin. For dentin, the hardness reduction was significant after just a 5-minute application time of the bleaching agent (LEWINSTEIN ET AL. 1994). In contrast, the use of sodium perborate combined with hydrogen peroxide did not alter the hardness. These results were further confirmed in a more recent study. It was found that not only 35% hydrogen peroxide gel and 30% hydrogen peroxide solution but also 35% carbamide peroxide gel decrease the microhardness of the external dentin layer; this influence was, however, relatively slight. The application of sodium perborate (mixed with water or 30% hydrogen peroxide) in the pulp cavity had no influence on the microhardness of dentin (CHNG ET AL. 2004).

Inside/outside Bleaching

This technique was first described by Settembrini et al. (SETTEMBRINI ET AL. 1997) and was later modified (LIEBENBERG 1997). As the name implies, the idea is to apply bleaching agent both on the external and internal surfaces of the tooth. The access cavity remains open during the entire treatment process. One advantage of this technique is that a low concentration of bleaching gel is sufficient to obtain the desired effect. First, a vacuum-drawn splint is made with reservoirs oral and vestibular to the tooth to be bleached. On the directly adjacent teeth, the model is ground down slightly in order to ensure that the bleaching splint fits these teeth tightly and prevents them from accidental exposure to bleaching gel. The fitting accuracy of the splint is checked on the patient. The access cavity is made as in the walking bleach technique. An impermeable base is important in order to ensure that the root-canal filling material is sealed. The patient is instructed in the use of the splint. Using a syringe, the access cavity and the corresponding location of the vacuum-drawn splint are filled with 10% carbamide peroxide (pea-sized amount of bleaching agent). The splint is inserted and the excess bleaching agent is removed with the fingertip or a cotton swab. The splint is worn at night – also to protect the open tooth. After a period of bleaching, the patient should clean the access cavity. Recall is recommended every two or three days to monitor the color change. When the desired color has been attained, the access cavity is cleaned and then closed with a provisional restoration material (glass-ionomer cement or polycarboxylate cement). A week later, the definitive restoration can be placed. Reasons for unsatisfactory results can often be found in patient compliance. Especially if the treatment duration is prolonged, the patient's compliance wanes (POYSER ET AL. 2004). This technique may be indicated where simultaneous bleaching of nonvital and vital teeth is possible and required (CARRILLO ET AL. 1998). Although bleaching success with the inside/outside technique may be greater in the first few days than with the walking bleach technique, after six months and the incident rehydration of the tooth,

the treatment results are equal (BIZHANG ET AL. 2003). A disadvantage is the lack of bacterial control during bleaching. The microorganisms can colonize the dentin tubules, and the danger exists that not only the bleaching result but also the long-term success of the endodontic treatment may be compromised.

In-Office Bleaching

This method is well-known from bleaching vital teeth, but it can also be employed for nonvital teeth. However, the predictability of the method is rather low. Chairside, rubber-dam is attached and 30% hydrogen peroxide is applied onto and in the tooth. Preparation of the access cavity and sealing of the root-canal is performed as in the walking bleach technique. After an application time of 15–20 minutes during which the bleaching gel is moved, the gel is rinsed off and the procedure is repeated, if necessary. The patient must wear protective eyeglasses to prevent droplets from contacting the eyes. Regrettably, the desired bleaching effect is often ephemeral, since the color lightening is predominantly produced by the tooth's dehydration under the rubber-dam. This agrees with experience gained in bleaching vital teeth. Here, too, the long-term success of at-home bleaching (longer application time by wearing a splint) is much better than that of in-office bleaching (DIETSCHI ET AL. 2006). An analysis of different bleaching methods of vital teeth showed that patients prefer at-home to in-office bleaching due to the shorter treatment time at the dentist's office (AUSCHILL ET AL. 2005). When using this method, a relatively large amount of hydrogen remains in the cavity due to the shorter, more concentrated application time; thus, the definitive closure of the access cavity should be performed in a subsequent appointment. The remaining hydrogen can also be completely eliminated in three minutes by applying catalase or other substances (e. g., ascorbic acid) (ROTSTEIN 1993, LAI ET AL. 2002).

Discussion

Given the appropriate indication, the bleaching of nonvital teeth is a relatively low-risk intervention to improve the esthetics of endodontically treated teeth. Depending on the situation, the walking bleach technique can be an uncomplicated and convenient method for both patients and dentists. In-office bleaching can often only produce short-term success, based largely on the dehydration of the tooth. The risk of root resorption cannot be exactly determined given the available data. Nevertheless, it seems clear that dental trauma favors cervical resorptions, and that this factor is probably more important than the application of bleaching agent. Sufficient cervical sealing and avoidance of the thermocatalytic method can minimize the risk of resorptions. Further development of the conventional bleaching agents by adding radical scavengers such as thiocarbamide or using sodium percarbonate seems promising in terms of minimizing the penetration of hydrogen into the periodontal space. Subsequent studies on the factors which favor the recurrence of discoloration after bleaching are certainly indicated.

Résumé

Le blanchiment des dents dont les racines ont été traitées pour améliorer l'aspect esthétique chez le patient est un traitement sans grand risque. Ce papier traite des causes de changements de couleur, des différentes techniques de traitement et des risques pour le patient. Quelques causes pour les décolorations

peuvent être influencées par le dentiste. Les trois méthodes les plus populaires pour la décoloration sont le *walking bleaching*, le *inside/outside bleaching* et la méthode de blanchir les dents directement dans le cabinet dentaire. La technique du *walking bleaching* est la technique la plus éprouvée et la moins pénible tant pour le dentiste que pour le patient. La technique de *inside/outside bleaching* peut être appliquée en combinaison avec un blanchiment des dents vitales et non vitales. Il existe encore des questions concernant les médicaments pour la décoloration. Des améliorations dans l'aspect de la sécurité restent possibles avec l'addition de thio-urée comme capteur de radi-

caux ou de substances plus récentes comme le percarbonate de sodium. L'application de la technique thermo-catalytique, un scellage cervical insuffisant et des médicaments à haute concentration doivent être évités parce que cela peut aggraver le risque de résorption des racines cervicales. Il faut informer les patients du faible taux de réussite de ce traitement et du risque d'une nouvelle décoloration. Le patient doit également être informé du risque de résorption cervicale. Il existe une grande corrélation entre résorption de racines et traumatisme dentaire.

References

- AMATO M, SCARAVILLI M S, FARELLA M, RICCITIELLO F: Bleaching teeth treated endodontically: long-term evaluation of a case series. *J Endod* 32: 376–378 (2006)
- ARENS D: The role of bleaching in esthetics. *Dent Clin North Am* 33: 319–336 (1989)
- ARI H, UNGÖR M: In vitro comparison of different types of sodium perborate used for intracoronary bleaching of discoloured teeth. *Int Endod J* 35: 433–436 (2002)
- ATTIN T, PAQUÉ F, AJAM F, LENNON Á M: Review of the current status of tooth whitening with the walking bleach technique. *Int Endod J* 36: 313–329 (2003)
- AUSCHILL T M, HELLWIG E, SCHMIDALE S, SCULEAN A, ARWEILER N B: Efficacy, side effects and patients' acceptance of different bleaching techniques (OTC, in-office, at-home). *Oper Dent* 30: 156–163 (2005)
- BARATIERI L N, RITTER A V, MONTEIRO S JR, CALDEIRA DE ANDRADA M A, CARDOSO VIEIRA L C: Nonvital tooth bleaching: guidelines for the clinician. *Quintessence Int* 26: 597–608 (1995)
- BARGHI N, GOLDWIN J M: Reducing the adverse effect of bleaching on composite-enamel bond. *J Esthet Dent* 6: 157–161 (1994)
- BASRANI B R, MANEK S, SODHI R N, FILLERY E, MANZUR A: Interaction between sodium hypochlorite and chlorhexidine gluconate. *J Endod* 33: 966–969 (2007)
- BIZHANG M, HEIDEN A, BLUNCK U, ZIMMER S, SEEMANN R, ROULET J F: Intracoronary bleaching of discoloured non-vital teeth. *Oper Dent* 28: 334–340 (2003)
- BORTOLUZZI E A, ARAÚJO G S, GUERREIRO TANOMARU J M, TANOMARU-FILHO M: Marginal gingival discoloration by grey MTA: a case report. *J Endod* 33: 325–327 (2007)
- BROWN G: Factors influencing successful bleaching of the discoloured root-filled tooth. *Oral Surg Oral Med Oral Pathol* 20: 238–244 (1965)
- BUSSADORI S K, ROTH F, GUEDES C C, FERNANDES K P, DOMINIQUE M M, WANDERLEY M T: Bleaching non-vital primary teeth: case report. *J Clin Pediatr Dent* 30: 179–182 (2006)
- CAMPS J, DE FRANCESCHI H, IDIR F, ROLAND C, ABOUT I: Time-course diffusion of hydrogen peroxide through human dentin: clinical significance for young tooth internal bleaching. *J Endod* 33: 455–459 (2007)
- CARRASCO L D, FRÖNER I C, CORONA S A M, PÉCORÀ J D: Effect of internal bleaching agents on dentinal permeability of non-vital teeth: quantitative assessment. *Dent Traumatol* 19: 85–89 (2003)
- CARRASCO L D, GUERISOLI D M, ROCHA M J, PÉCORÀ J D, FRÖNER I C: Efficacy of intracoronary bleaching techniques with different light activation sources. *Int Endod J* 40: 204–208 (2007)
- CARRILLO A, ARREDONDO TREVINO M V, HAYWOOD V B: Simultaneous bleaching of vital teeth and an open-chamber nonvital tooth with 10% carbamide peroxide. *Quintessence Int* 29: 643–648 (1998)
- CASEY L J, SCHINDLER W G, MURATA S M, BURGESS J O: The use of dentinal etching with endodontic bleaching procedures. *J Endod* 15: 535–538 (1989)
- CHNG H K, YAP A U, WATTANAPAYUNGKUL P, SIM C P: Effect of traditional and alternative bleaching agents on microhardness of human dentine. *J Oral Rehabil* 31: 811–816 (2004)
- CVEK M, LINDWALL A M: External root resorption following bleaching of pulpless teeth with oxygen peroxide. *Endod Dent Traumatol* 1: 56–60 (1985)
- DAHLSTROM S W, HEITERSAY G S, BRIDGES T E: Hydroxyl radical activity in thermo-catalytically bleached root-filled teeth. *Endod Dent Traumatol* 13: 119–125 (1997)
- DELIPERI S, BARDWELL D N: Two-year clinical evaluation of non-vital tooth whitening and resin composite restorations. *J Esthet Restor Dent* 17: 369–378 (2005)
- DEMARCO F F, FREITAS J M, SILVA M P, JUSTINO L M: Microleakage in endodontically treated teeth: influence of calcium hydroxide dressing following bleaching. *Int Endod J* 34: 495–500 (2001)
- DE OLIVEIRA L D, CARVALHO C A, HILGERT E, BONDIOLI I R, DE ARAÚJO M A, VALERA M C: Sealing evaluation of the cervical base in intracoronary bleaching. *Dent Traumatol* 19: 309–313 (2003)
- DIETSCHI D: Nonvital bleaching: general considerations and report of two failure cases. *Eur J Esthet Dent* 1: 52–61 (2006)
- DIETSCHI D, ROSSIER S, KREICI I: In vitro colorimetric evaluation of the efficacy of various bleaching methods and products. *Quintessence Int* 37: 515–526 (2006)
- FARMER D S, BURCHAM P, MARIN P D: The ability of thiourea to scavenge hydrogen peroxide and hydroxyl radicals during the intracoronary bleaching of bloodstained root-filled teeth. *Aust Dent J* 51: 146–152 (2006)
- FASANARO T S: Bleaching teeth: history, chemicals and methods used for common tooth discolorations. *J Esthet Dent* 4: 71–78 (1992)
- FAUNCE F: Management of discolored teeth. *Dent Clin North Am* 27: 657–670 (1983)
- FEIGLIN B: A 6-year recall study of clinically chemically bleached teeth. *Oral Surg Oral Med Oral Pathol* 63: 610–613 (1987)
- FRIEDMAN S: Internal bleaching: long-term outcomes and complications. *J Am Dent Assoc* 128: 265–305 (1997)
- FRIEDMAN S, ROTSTEIN I, LIBFELD H, STABHOLZ A, HELING I: Incidence of external root resorption and esthetic results in 58 bleached pulpless teeth. *Endod Dent Traumatol* 4: 23–26 (1988)
- GLOCKNER K, HULLA H, EBERLESEDER K, STÄDTLER P: Five year follow-up of internal bleaching. *Braz Dent J* 10: 105–110 (1999)
- GOLDSTEIN G R, KIREMIDIJAN-SCHUMACHER L: Bleaching: is it safe and effective? *J Prosthet Dent* 69: 325–328 (1993)
- GOLDSTEIN R E: In-office bleaching: where we came from, where we are today. *J Am Dent Assoc* 128: 115–155 (1997)
- GONTIJO I T, NAVARRO R S, CIAMPONI A L, ZEZZEL D: Whitening techniques using the diode laser and halogen lamp in human devitalized primary teeth. *J Dent Child* 75: 164–167 (2008)
- HARRINGTON G W, NATKIN E: External root resorption associated with bleaching of pulpless teeth. *J Endod* 5: 344–48 (1979)
- HEITERSAY G S: Invasive cervical resorption: an analysis of potential predisposing factors. *Quintessence Int* 30: 83–95 (1999)
- HEITERSAY G S, DAHLSTROM S W, MARIN P D: Incidence of invasive cervical resorption in bleached root-filled teeth. *Aust Dent J* 39: 82–87 (1994)
- HOLMSTRUP G, PALM A M, LAMBJERG-HANSEN H: Bleaching of discoloured root-filled teeth. *Endod Dent Traumatol* 4: 197–201 (1988)
- HOSOYA N, COX C F, ARAI T, NAKAMURA J: The walking bleach procedure: an in vitro study to measure microleakage of five temporary sealing agents. *J Endod* 26: 716–718 (2000)
- JACOBOWITZ M, DE LIMA R K: Treatment of inflammatory internal root resorption with mineral trioxide aggregate: a case report. *Int Endod J* 41: 905–912 (2008)
- KANEKO J, INOUE S, KAWAKAMI S, SAMO H: Bleaching effect of sodium percarbonate on discolored pulpless teeth in vitro. *J Endod* 26: 25–28 (2000)
- KEHOE J C: pH reversal following in vitro bleaching of pulpless teeth. *J Endod* 13: 16–19 (1987)

- KIM S T, ABBOTT P V, MC GINLEY P:** The effects of Ledermix paste on discolouration of immature teeth. *Int Endod J* 33: 233–237 (2000a)
- KIM S T, ABBOTT P V, MC GINLEY P:** The effects of Ledermix paste on discolouration of mature teeth. *Int Endod J* 33: 227–232 (2000b)
- LADO E A, STANLEY H R, WEISMAN M I:** Cervical resorption in bleached teeth. *Oral Surg* 55: 78–80 (1983)
- LAI S C N, TAY F R, CHEUNG G S, MA Y F, CARVALHO R M, WEI S H Y, TOLEDANO M, OSORIO R, PASHLEY D H:** Reversal of compromised bonding in bleached enamel. *J Dent Res* 81: 477–481 (2002)
- LATCHAM N L:** Postbleaching cervical resorption. *J Endod* 12: 262–265 (1986)
- LATCHAM N L:** Management of a patient with postbleaching cervical resorption. A clinical report. *J Prosthet Dent* 65: 603–605 (1991)
- LEWINSTEIN I, HIRSCHFELD Z, STABHOLZ A, ROTSTEIN I:** Effect of hydrogen peroxide and sodium perborate on the microhardness of human enamel and dentin. *J Endod* 22: 23–25 (1994)
- LIEBENBERG W H:** Intracoronal lightening of discolored pulpless teeth: a modified walking bleach technique. *Quintessence Int* 28: 771–777 (1997)
- LIM M Y, LUM S O Y, POH R S C, LEE G P, LIM K-C:** An in vitro comparison of the bleaching efficacy of 35% carbamide peroxide with established intracoronal bleaching agents. *Int Endod J* 37: 483–488 (2004)
- LOXLEY E C, LIEWEHR F R, BUXTON T B, MCPHERSON J C 3rd:** The effect of various intracanal oxidizing agents on the push-out strength of various perforation repair materials. *Oral Surg Oral Pathol Oral Radiol Endod* 95: 490–494 (2003)
- MARIN P D, BARTOLD P M, HEITERSAY G S:** Tooth discoloration by blood: an in vitro histochemical study. *Endod Dent Traumatol* 13: 132–138 (1997)
- MÜLLER ARCARI G, ARAÚJO E, BARATIERI L N, LOPES G C:** Microtensile bond strength of a nanofilled composite resin to human dentin after nonvital tooth bleaching. *J Adhes Dent* 9: 333–340 (2007)
- NUTTING E B, POE G S:** Chemical bleaching of discolored endodontically treated teeth. *Dent Clin North Am* 11: 655–622 (1967)
- PARSONS J R, WALTON R E, RICKS-WILLIAMSON L:** In vitro longitudinal assessment of coronal discoloration from endodontic sealers. *J Endod* 27: 699–702 (2001)
- PARTOVI M, AL-HAVVAZ A H, SOLEIMANI B:** In vitro computer analysis of crown discoloration from commonly used endodontic sealers. *Aust Endod J* 32: 116–119 (2006)
- PEARSON H H:** Successful bleaching without secondary discoloration. *J Can Dent Assoc (Tor)* 17: 200–201 (1951)
- PLOTINO G, BUONO G, GRANDE N M, PAMEIER C H, SOMMA F:** Nonvital tooth bleaching: a review of the literature and clinical procedures. *J Endod* 34: 394–407 (2008)
- POYSER N J, KELLEHER M G, BRIGGS P F:** Managing discoloured non-vital teeth: the inside/outside bleaching technique. *Dent Update* 31: 204–210, 213–214 (2004)
- RIBEIRO D A, DUARTE M A, MATSUMOTO M A, MARQUES M E, SALVADORI D M:** Biocompatibility in vitro tests of mineral trioxide aggregate and regular white portland cements. *J Endod* 31: 605–607 (2005)
- RIBEIRO D A, SUGUI M M, MATSUMOTO M K, DUARTE M A, MARQUES M E, SALVADORI D M:** Genotoxicity and cytotoxicity of mineral trioxide aggregate and regular portland cements on chinese hamster ovary (cho) cells in vitro. *Oral Surg Oral Med Oral Pathol Oral Radiol Endod* 101: 258–261 (2006)
- ROTSTEIN I:** Role of catalase in the elimination of residual hydrogen peroxide following tooth bleaching. *J Endod* 19: 567–569 (1993)
- ROTSTEIN I, MOR C, FRIEDMANN S:** Prognosis of intracoronal bleaching with sodium perborate preparations in vitro: 1-year study. *J Endod* 19: 10–12 (1993)
- ROTSTEIN I, TOREK Y, MISGAV R:** Effects of cementum defects on radicular penetration by 30% hydrogen peroxide during intra-coronal bleaching. *J Endod* 17: 230–210 (1991a)
- ROTSTEIN I, ZALKIND M, MOR C, TARABEAH S, FRIEDMANN S:** In vitro efficacy of sodium perborate preparations used for intracoronal bleaching of discoloured non-vital teeth. *Endodont Dent Traumatol* 7: 177–180 (1991b)
- SETTEMBRINI L, GULTZ J, KAIM J, SCHERER W:** A technique for bleaching non vital teeth: inside/outside bleaching. *J Am Dent Assoc* 128: 1283–1284 (1997)
- SPASSER H F:** A simple bleaching technique using sodium perborate. *New York State Dent J* 27: 332–334 (1961)
- SUNG E C, CHAN S M, MITO R, CAPUTO A A:** Effect of carbamide peroxide bleaching on the shear bond strength of composite to dental bonding agent enhanced enamel. *J Prosthet Dent* 82: 595–599 (1999)
- TAY F R, PASHLEY D H, DAY T E, NGOH E C, BRESCHI L:** Potential iatrogenic tetracycline staining of endodontically treated teeth via NaOCl/MTAD irrigation: a preliminary report. *J Endod* 32: 354–58 (2006)
- THORDARSON A, ZACHRISSON B U, MjÖR I A:** Remodeling of canines to the shape of lateral incisors by grinding: a long-term clinical and radiographic evaluation. *Am J Orthod Dentofacial Orthop* 100: 123–132 (1991)
- TINAZ A C, KIVANÇ B H, GÖRGÜL G:** Staining of calcium hydroxide and monochlorophenol following removal of AH26 root canal sealer. *J Contemp Dent Pract* 9: 56–63 (2008)
- YUI K C, RODRIGUES J R, MANCINI M N, BALDUCCI I, GONÇALVES S E:** Ex vivo evaluation of the effectiveness of bleaching agents on the shade alteration of blood-stained teeth. *Int Endod J* 41: 485–492 (2008)
- VACHON C, VANEK P, FRIEDMAN S:** Internal bleaching with 10% carbamid peroxide in vitro. *Pract Periodontics Aesthet Dent* 10: 1145–1154 (1998)
- VAN DER BURGT T P, ERONAT C, PLASSCHAERT A J:** Staining patterns in teeth discolored by endodontic sealers. *J Endod* 12: 187–191 (1986a)
- VAN DER BURGT T P, MULLANEY T P, PLASSCHAERT A J:** Tooth discoloration induced by endodontic sealers. *Oral Surg Oral Med Oral Pathol* 61: 84–89 (1986b)
- VAN DER BURGT T P, PLASSCHAERT A J:** Bleaching of tooth coloration caused by endodontic sealers. *J Endod* 12: 231–234 (1986)
- VAN DER BURGT T P, PLASSCHAERT A J:** Tooth discoloration induced by dental materials. *Oral Surg Oral Med Oral Pathol* 60: 666–669 (1985)
- WATTS A, ADDY M:** Tooth discoloration and staining. A review of literature. *Br Dent J* 190: 309–316 (2001)