

THOMAS G. WOLF¹
 FRANK PAQUÉ²
 PATRICK BETZ¹
 BRITA WILLERSHAUSEN¹
 BENJAMÍN
 BRISEÑO-MARROQUÍN¹

¹ Department of Operative Dentistry, Johannes Gutenberg University Medical Center Mainz, Germany

² Division of Preventive Dentistry, Periodontology, and Cariology, University of Zurich, Center of Dental Medicine Zurich, Switzerland

CORRESPONDENCE

Dr. Thomas G. Wolf
 Poliklinik für Zahnerhaltungskunde und Parodontologie
 Universitätsmedizin der Johannes Gutenberg-Universität Mainz
 Augustusplatz 2
 D-55131 Mainz
 Tel. +49 6131 173501
 Fax +49 6131 173406
 e-mail: thomaswolf@uni-mainz.de

SWISS DENTAL JOURNAL SSO 127: 513–519 (2017)

Accepted for publication: 9 February 2017

Micro-CT assessment of internal morphology and root canal configuration of non C-shaped mandibular second molars

KEYWORDS

Internal tooth morphology
 Mandibular second molar
 Micro-computed tomography
 Root canal configuration

SUMMARY

The root canal system morphology of the mandibular second molar was investigated by means of micro-computed tomography (μ CT). The root canal configuration (RCC), foramina and accessory canals frequency of 93 mandibular second molars of an Egyptian sample were investigated by μ CT scans. The RCC and main foramina number (MFN) are described by means of a four-digit system from coronal to apical. The most frequently observed RCCs in the mesial root were 2–2–1/1 (32.3%), 2–2–2/2 (28.0%), 1–1–1/1 (6.5%) and 2–1–1/1 (6.5%); an additional twelve different RCCs were also found here. In the distal root, the RCC 1–1–1/1 was observed in 81.7%; another ten different RCCs with a frequency of less than 5% were also observed in this root. Anastomoses between the mesiobuccal and mesiolingual canals

in the mesial root were witnessed in the coronal (20.5%), middle (19.4%) and apical (10.8%) thirds. Accessory canals were found in the coronal (mesiobuccal 15.0%, mesiolingual 12.9%, distobuccal 1.1%), middle (mesiobuccal 7.5%, mesiolingual 10.8%, distolingual 3.3%) and apical (mesiobuccal 19.3%, mesiolingual 16.2%, distolingual 10.8%, distobuccal 2.2%) thirds. The RCC of mandibular second molars showed a great variety. When compared with the first mandibular molar in a historical control from the same sample, the mandibular second molar presented less morphological diversifications. Yet, the mesial root canal system of the mandibular second molar showed more RCC variations, connecting and accessory canals than the distal root.

Introduction

Successful endodontic treatment demands a profound knowledge of the internal tooth morphology by all means (VERTUCCI 1984). Detailed morphology information should be considered as the foundation for understanding the three-dimensional concept of the root canal system, thus disclosing its significance for clinical endodontic therapy (SCHILDER 1967; SCHILDER 1974). Although others (SHEMESH ET AL. 2016) have reported on the morphology of C-shaped root canals of mandibular second molars by means of cone-beam computed tomography, to the best of our knowledge, the tooth morphology and root canal configuration of non C-shaped mandibular second molars has hitherto not been investigated sufficiently by microcomputed tomography (micro-CT). Microcomputed tomography is a non-destructive and reproducible *ex-vivo* research method and is considered as the research method that offers the foremost possibility for an accurate examination of the morphology of the root canal system (RHODES ET AL. 1999; PLOTINO ET AL. 2006). In comparison to other research methods, additional information on the morphological structures is provided by a noninvasive, high-resolution technique combined with a 3D-image rendering software (RHODES ET AL. 1999; PLOTINO ET AL. 2006; CHANG ET AL. 2013). According to the information gained through the literature, micro-CT has tremendous potential in endodontic research and the ability to accurately present the internal and external morphology of teeth, in detail for using to examine the root canal configurations, lengths, curvature and location of details like calcified segments (NIELSEN ET AL. 1995; PARK ET AL. 2009; DOMARK ET AL. 2013). The objective information obtained by this *ex-vivo* method, when compared to other research methodologies such as the clearing technique or conventional radiographic method, is certainly contributory to identify difficulties prior to and during endodontic treatment, thus minimizing and avoiding iatrogenic errors. The root canal configuration has been described in literature with different classification systems; Vertucci's (VERTUCCI 1984) classification system is probably the most frequently employed (CALIŞKAN ET AL. 1995; RWENYONYI ET AL. 2009; BARSNESS ET AL. 2015). Unfortunately this and other classification systems are not capable to accurately describe some morphological configuration variations. The current study aimed at analyzing the internal morphology of mandibular second molars by means of micro-computed tomography and at classifying their root canal configuration using a classification system described and employed in previous studies (BRISEÑO-MARROQUÍN ET AL. 2015; WOLF ET AL. 2016; WOLF ET AL. 2017).

Materials and Methods

Tooth selection

Ninety-three extracted human permanent mandibular second molars were obtained from dental clinics and dental practitioners for reasons unrelated to the present study, and stored in 5.25% sodium hypochlorite. Out of a greater sample number, all teeth included in the study could be clearly identified as mandibular second molars with clear distinct roots and a mesiodistal crown diameter of 10.5 mm (± 0.2) (JORDAN ET AL. 1992). The teeth obtained were from an Egyptian population (MARROQUÍN ET AL. 2004). The selection criteria were: absence of signs of root fracture or resorption, complete crown and root development, no radicular or coronal caries and no restorations or endodontic treatment. The gender of the sample was unknown and an approximate teeth age determination was not undertaken.

Due to a relatively low number of second molars with C-shaped ($n = 4$) morphology as well as with radix ento- ($n = 1$) or paramolaris that were identified in the original teeth sample and because of their complex root canal morphology, these were not included in this investigation. The teeth were cleaned of any attached hard and soft tissues as well as calculus by means of an ultrasonic scaler, placed for one hour in a 3% hydrogen peroxide ultrasonic bath and stored in 70% alcohol. For further internal morphology investigation of the teeth, endodontic access cavities, to establish the root canal entrance location and number, were prepared (the results of this investigation are not included in this report) with a high-speed hand piece using a diamond round bur 801-014 (Komet, Lemgo, Germany). The pulp chamber roof was carefully removed by cutting along the pulp chamber walls. When required, ultrasonic tips were used to remove pulp stones. The pulp chambers were rinsed with 1% sodium hypochlorite (60 sec) and dried through suction.

Morphological analysis by means of microcomputed tomography

The teeth were scanned at an isotropic resolution of 20 μm in a desktop μCT unit (μCT 40; Scanco Medical, Brüttisellen, Switzerland) by means of a previously established method (PAQUÉ ET AL. 2009; PAQUÉ & PETERS 2011; PAQUÉ ET AL. 2012) at settings of 70 kV and 114 μA resulting in 800 to 1,200 slices per tooth. To be able to differentiate the tooth structure, the obtained images were visualized through depiction in dummy colors in the 3D reconstructions of the micro-computed tomography scans by means of a rendering software (VGStudio Max 2.2; Volumegraphics, Heidelberg, Germany). The pulp chamber and root canal system were coded with red, the coronal enamel with white and the dentin with transparent grey (Figs. 1 and 2).

The root canal configuration was described dividing the root into thirds. The first, second and third configuration digit provide the coronal, middle and apical third root canal number at the coronal limit of the respective third. The fourth digit is separated with a slash and indicates the main foramina number. Main foramina were defined as foramina which emerged from the same canal as the apical terminus and in which the measured diameter difference between the foramina was no less than 0.2 mm. The foramina diameter results are intended to be reported in a subsequent manuscript. The number of accessory canals and anastomoses as well as the number of apical accessory foramina observed under micro-computed tomography were also recorded. The results are expressed as absolute and relative values according to the sample number.

Results

The registered root canal configuration of the mesial and distal roots is shown in Tab. I. The most frequently observed root canal configurations in the mesial root were 2-2-1/1 (32.3%), 2-2-2/2 (28.0%) as well as 1-1-1/1 and 2-1-1/1 (6.5% each). An additional twelve different root canal configurations were found in this root with a frequency of less than 5%. In the distal root, the most frequently witnessed root canal configuration was 1-1-1/1 (81.7%). An additional ten root canal configurations with less than 5% each were also identified in this root.

The number of accessory canals and anastomoses observed in the coronal third of the mesial and distal root is shown in Tab. II. While the mesiobuccal and mesiolingual canals had no accessory canals in 92.5 and 89.2% in the coronal and 84.9 and 87.1% in the middle third, in the distobuccal canal one to two acces-

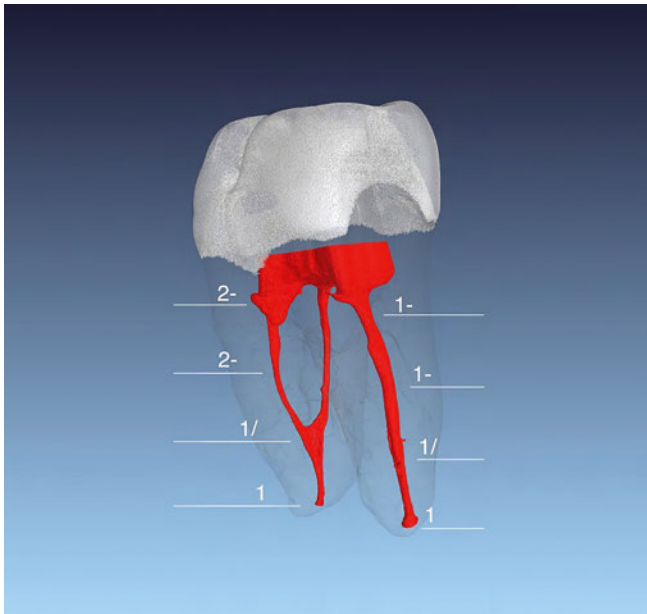


Fig.1 The mesial root (left) of this mandibular second molar has a 2-2-1/1 root canal configuration. The distal root canal shows a 1-1-1/1 configuration. Accessory foramina were observed in 12.3% in the distal root canal. In Figure 1, two accessory root canals can be observed in the middle third of the apex.

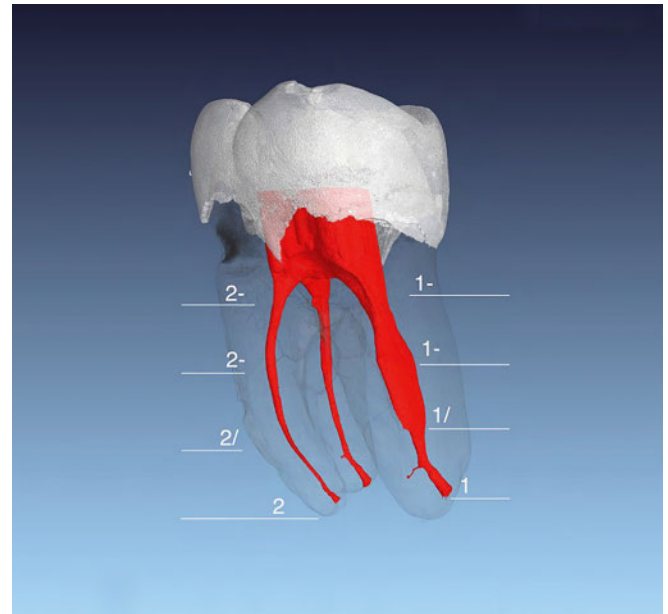


Fig.2 The root canal configuration of the distal root (right) of this mandibular second molar is a 1-1-1/1. An accessory foramen can be observed in the apical third of the root. An oval-shaped root canal is a frequent morphology found in this type of teeth. The mesial root canal configuration (2-2-2/2) is frequently more complex than those of the distal root. Figure 2 shows two separate root canals, one accessory foramen can be observed in the apical third of the root.

Tab.1 Root canal configuration observed under μ CT in the mesial and distal roots of mandibular second molars (n = 93). The root canal configuration numbers from left to right describe the root canal path from the coronal to the middle and apical thirds, respectively. The last digit, separated by a slash, shows the number of main foramina observed.

Mandibular second molar/Root canal configuration frequency					
Mesial root			Distal root		
Configuration	Absolute	Mean	Configuration	Absolute	Mean
2-2-1/1	30	32.3	1-1-1/1	76	81.7
2-2-2/2	26	28.0	1-1-2/2	3	3.2
1-1-1/1	6	6.5	2-2-2/2	3	3.2
2-1-1/1	6	6.5	1-2-1/1	2	2.2
2-3-2/2	4	4.3	1-2-2/2	2	2.2
1-1-2/2	3	3.2	2-1-1/1	2	2.2
1-2-1/1	3	3.2	1-1-1/3	1	1.1
2-1-2/2	3	3.2	1-1-2/1	1	1.1
2-3-1/1	3	3.2	1-3-1/1	1	1.1
1-2-2/2	2	2.2	2-1-2/2	1	1.1
2-2-1/2	2	2.2	2-2-3/3	1	1.1
2-2-2/1	1	1.1			
2-2-2/4	1	1.1			
2-2-3/3	1	1.1			
3-2-1/1	1	1.1			
3-3-2/2	1	1.1			

sory canals were observed in 3.3% in the coronal and in 1.1% in the middle third of the root. In the coronal third of the distobuccal canal and in middle third of the distolingual canal, no accessory canals were found. The mesiobuccal (7.5%) and mesiolingual (10.8%) canals had one accessory canal in the middle third. The distobuccal canal had none, while the distolingual canal had only one or two accessory canals in 3.3%. A connecting canal between the mesiobuccal and mesiolingual canals was observed in 19.4% in the coronal and in 20.5% in the middle third (Tab. III). The number of accessory canals and anastomoses and foramina in the apical third are shown in Tab. IV. The mesiobuccal and mesiolingual canals showed one or two accessory canals in 19.3% and 16.2%, respectively. In the distolingual (10.8%) and distobuccal (2.2%) canals at least one accessory canal was found.

Discussion

Knowledge of the three-dimensional root canal system is an essential prerequisite for endodontic clinical decision-making. Deciding upon the right treatment, instrumentation and filling techniques is only possible when the dental practitioner has a thorough understanding of the internal morphology of the root canal system. Thus, it is important to gather as much knowledge as possible to ensure successful outcome of endodontic surgical and nonsurgical treatments. A three-dimensional conception of the root canal system provides more detailed information of the root canal morphology when compared with conventional methods such as clearing or two-dimensional methods. Three-dimensional systems also provide additional information of minor structures such as accessory canals and anastomoses as well as foramina. Micro-computed tomography

Tab. II Number (n) and mean (%) of accessory canals (AC) and anastomoses (AS) observed in the coronal third under microcomputed tomography of mandibular second molars (n = 93).

	AC				AS		AC			
	MB		ML		Connecting (MB-ML)		DL		DB	
	n	%	n	%	n	%	n	%	n	%
0	86	92.5	83	89.2	75	80.6	90	96.8	93	100.0
1	7	7.5	10	10.8	15	16.1	2	2.2		
2					2	2.2	1	1.1		
3					1	1.1				

Tab. III Number (n) and mean (%) of accessory canals (AC) and anastomoses (AS) observed in the middle third under microcomputed tomography of second mandibular molars (n = 93).

	AC				AS		AC			
	MB		ML		Connecting (MB-ML)		DL		DB	
	n	%	n	%	n	%	n	%	n	%
0	79	84.9	81	87.1	74	79.6	93	100.0	92	98.9
1	11	11.8	12	12.9	13	14.0			1	1.1
2	3	3.2			3	3.2				
3					2	2.2				
4					1	1.1				

Tab. IV Number (n) and mean (%) of anastomoses (AS) and accessory foramina (AF) observed in the apical third under microcomputed tomography of mandibular second molars (n = 93).

	AF				AS		AF			
	MB		ML		Connecting (MB-ML)		DL		DB	
	n	%	n	%	n	%	n	%	n	%
0	75	80.6	78	83.9	83	89.2	83	89.2	91	97.8
1	15	16.1	13	14.0	9	9.7	9	9.7	2	2.2
2	3	3.2	2	2.2	1	1.1				
3							1	1.1		

is a noninvasive, nondestructive and reproducible *ex-vivo* investigation method that offers these possibilities (RHODES ET AL. 1999; PLOTINO ET AL. 2006).

In the present study, various anomalies of the root canal configuration were found in both the mesial and distal roots of mandibular second molars. However, 14 additional root canal configurations were observed (39.7%) in the mesial root (2-2-1/1 [32.3%] and 2-2-2/2 [28%]). Our results for both configurations are similar to those of Vertucci (VERTUCCI 1984), Sert & Bayirli (SERT & BAYIRLI 2004) and Gulabivala et al. (GULABIVALA 2001), ranging from 35.9 to 38.0 and 23.0 to 26.9%, respectively. Pineda & Kuttler (PINEDA & KUTTLER 1972) published similar results (26.0%), yet the reported root canal configuration was 2-2-2/1 instead of 2-2-2/2. Caliřkan et al. (CALIřKAN ET AL. 1995), Rwenyonyi et al. (RWENYONYI ET AL. 2009), Weine et al. (WEINE ET AL. 1988) and Ahmed et al. (AHMED ET AL. 2007) reported contrasting lower (CALIřKAN ET AL. 1995) or higher (RWENYONYI ET AL. 2009; WEINE ET AL. 1988; AHMED ET AL. 2007) results of root canal configuration, ranging from 18.0 to 52.0 and 40.0 to 63.0%, respectively. In the distal root, besides the most predominant root canal configuration (1-1-1/1 in 81.7%), an additional ten root canal configuration variations were observed. The 1-1-1/1 root canal configuration frequency reported in this study is consistent with findings, ranging from 70.0 to 94.4%, published by Caliřkan et al. (CALIřKAN ET AL. 1995), Sert & Bayirli (SERT & BAYIRLI 2004), Pineda & Kuttler (PINEDA & KUTTLER 1972), Rwenyonyi et al. (RWENYONYI ET AL. 2009), Weine et al. (WEINE ET AL. 1988) and Gulabivala et al. (GULABIVALA ET AL. 2001). The differences between the results of various studies can be explained through the different methods of investigation employed, evaluation parameters and origin of samples. Although “c-shaped” root canal morphology has been repeatedly described in the literature (GAO ET AL. 2006; MIN ET AL. 2006; AMOROSO-SILVA ET AL. 2015), these types of teeth were not contained in the sample of this investigation. A separate report for this type of teeth is being planned. Compared with the results of the mandibular first molar (n = 118) in another investigation (WOLF ET AL. 2016) in both, the mesial and distal roots, more different root canal configurations, accessory canals and anastomoses in coronal third were observed; yet, less variations of these structures as well as accessory apical foramina in middle and apical thirds of the root could be detected. However, this fact does not necessarily imply that mandibular second molars might be easier to treat clinically than mandibular first molars. Within the limitations of the present micro-computed tomography *ex-vivo* study and due to the individual morphology of each tooth, a large amount of anatomical variations is possible. In this study only the anatomical treatment challenges can be considered, the solutions must be generated for each particular case. Our results showed that accessory canals and anastomoses in the mesial and distal root canal system could be observed in the coronal (mesial 7.5 and 10.8%; distal 3.3 and 0%, respectively) and middle (mesial 15.0 and 12.9%; distal 0 and 1.1%, respectively) thirds of both roots. Anastomoses (10.8%) as well as accessory foramina were determined in the apical third in both roots (mesial 19.3 and 16.2%; distal 10.8 and 2.2%, respectively). Barsness and co-workers (BARSNESS ET AL. 2015) also investigated the mandibular second molars by means of micro-computed tomography (n = 18) and reported the prevalence of contrasting accessory canals and anastomoses in the mesial (55.6%) and in the distal (38.9%) roots in the apical region. The results of De Deus (DE DEUS 1975) (n = 80) with 0%

accessory canals and 17.5% secondary canals in the apical region, Rwenyonyi et al. (RWENYONYI ET AL. 2009) with lateral (0.1%) and connecting (“intercanal communication”; 7.6%) canals and multiple apical foramina (2.2%) (n = 223) as well as Gulabivala et al. (GULABIVALA ET AL. 2001) with a 0.9, 4.2 and 11.3% of lateral canals in the coronal, middle and apical thirds, respectively, are also in contrast with ours. These authors employed a different investigation methodology; nevertheless, the resulting differences could also be explained by means of the sample size, ethnical origin, age or gender. Barsness et al. (BARSNESS ET AL. 2015) suggested that a higher prevalence could be explained through the detailed imaging method offered by micro-computed tomography.

Although the sample number in the present study is higher, and the research methodology is different, our results (coronal 19.4%, middle 20.5%, apical 10.8%) are higher when compared with the aforementioned study (RWENYONYI ET AL. 2009). However, they are not as high (mesial root 55.1%) or as low (distal root 2.6%) as those reported by Gulabivala et al. (GULABIVALA ET AL. 2001). The apical foramina (one canal 70.3%, two canals 25.5%, three canals 3.7% and four canals 0.5%) reported by Gulabivala et al. (GULABIVALA ET AL. 2001) are also higher than those of the present study (mesiobuccal and mesiolingual one or two canals in 19.3 and 16.2%, respectively; distolingual and distobuccal one or three canals in 10.8 and 2.2%, respectively). The incidence of accessory canals and anastomoses as well as accessory foramina reported in the literature (RWENYONYI ET AL. 2009; GULABIVALA ET AL. 2001; DE DEUS 1975) emphasizes the importance of a compulsory thorough chemomechanical debridement of the root canal system areas (BYSTRÖM & SUNDQVIST 1981), where it cannot be done mechanically. The consequence of not achieving this goal would most likely be a tedious re-treatment, surgical procedures or even tooth extraction. Therefore, to prevent iatrogenic errors, an internal morphological overview of a great sample number of mandibular second molars examined by micro-computed tomography is provided in the current study. The presented information supports an accurate understanding and knowledge of the root canal anatomy of mandibular second molars and assists practitioners to cope with difficult surgical and nonsurgical endodontic treatment tasks.

Conclusions

- The most commonly observed root canal configurations in the mesial root were 2-2-1/1 in 32.3% and 2-2-2/2 in 28.0%.
- In distal root, the most commonly observed root canal configuration was 1-1-1/1 in 81.7%.
- Anastomoses in the mesial root were found in 19.4% of coronal, 20.5% of middle and 10.8% of apical thirds.
- The mesiobuccal and mesiolingual root canals had no accessory canals in the coronal third in 84.9 and 87.1%, respectively.
- The middle third of the mesiobuccal (11.8%) and mesiolingual (12.9%) root canals had only one accessory canal.
- The mesiobuccal and mesiolingual root canals showed one or two accessory foramina in 19.3 and 16.2%, respectively; the distolingual and distobuccal root canals had at least one accessory foramina in 10.8 and 2.2%, respectively.

Acknowledgements

We thank our colleague and friend Dr. Ann Katrin Reuter for her kind assistance with the manuscript.

Résumé

Introduction

Un traitement endodontique réussi demande un savoir précis de la morphologie dentaire intérieure. Des informations anatomiques détaillées sont la base pour la compréhension du système du canal radiculaire à trois dimensions. Ils constituent l'exigence pour prendre une décision d'un traitement chirurgical ou non chirurgical. Jusqu'à présent, la littérature discute rarement la morphologie et la configuration du canal radiculaire des deuxième molaires mandibulaires.

Aujourd'hui il nous est possible avec l'aide d'un ordinateur microtomographique (micro-CT) et de son logiciel 3D d'examiner précisément le système du canal radiculaire. Le micro-CT est considéré comme une méthode de recherche non destructive et ex vivo, qui, comparée à d'autres méthodes conventionnelles, nous donne une information complémentaire de la structure morphologique.

Matériel et méthodes

La configuration du canal radiculaire, le nombre de foramina et les canaux accessoires de 93 deuxième molaires mandibulaires ont été analysés. La configuration du canal radiculaire et le nombre de foramina ont été décrits de la couronne à la racine à l'aide d'un code à quatre chiffres. Les trois premiers chiffres représentent la partie coronale, le milieu et la partie apicale du système du canal radiculaire. Le quatrième chiffre est séparé par une barre oblique et donne le nombre de foramina principaux.

Résultats

Les configurations du canal radiculaire les plus fréquemment observées dans la racine mésiale étaient 2-2-1/1 (32,3%), 2-2-2/2 (28,0%), 1-1-1/1 (6,5%) et 2-1-1/1 (6,5%). Douze autres configurations différentes ont été observées. Dans la racine distale, la configuration observée le plus souvent était 1-1-1/1 avec 81,7%. Avec une densité de moins de 5%, dix autres configurations ont été observées dans cette même racine.

Des anastomoses dans la racine mésiale entre les canaux mésio-buccal (MB) et mésio-lingual (ML) ont pu être identifiées à 20,5% dans le tiers coronale, à 19,4% au milieu et à 10,8% dans le tiers apical. Des canaux radiculaires accessoires ont été observés dans le tiers coronal (MB 15,5%, ML 12,9%, disto-buccal [DB] 1,1%), au milieu (MB 7,5%, ML 10,8%, disto-lingual [DL] 3,3%) et dans le tiers apical (MB 19,3%, ML 16,2%, DL 10,8%).

Discussion

Dans la discussion littéraire, les résultats de cette recherche ont été comparés à d'autres études. Les résultats différents entre ces études sont dus aux différentes méthodes de recherche, aux paramètres d'évaluation et à l'origine des échantillons utilisés. Dans cette étude il s'agit d'un échantillon égyptien. Des études préliminaires ont comparé cet échantillon à ceux d'Europe centrale. Concernant la configuration du canal radiculaire des ressemblances ont été observées et cet échantillon a été choisi pour une recherche plus approfondie.

Résumant le tout, la configuration du canal radiculaire des deuxième molaires mandibulaires était très différente dans cette étude. Elles montraient moins de diversifications morphologiques que les premières molaires. Cependant le système du canal radiculaire de la racine mésiale avait plus de configurations des canaux radiculaires et accessoires que la racine distale.

La présence de canaux accessoires et foramina comme des anastomoses souligne l'importance d'un nettoyage chimio-

mécanique et approfondi du système du canal radiculaire, surtout dans les endroits qui ne peuvent pas être préparés mécaniquement. La non-réalisation de ce but mènerait à un traitement rigoureux, à des interventions chirurgicales ou même à une extraction.

Pour éviter les erreurs iatrogènes, un grand échantillon de deuxième molaires mandibulaires qui ont été examinées par micro-CT a été fourni. Les informations présentées nous donnent un savoir précis et compréhensible de l'anatomie de la racine des deuxième molaires mandibulaires. Les informations fournies doivent pouvoir aider les praticiens à prendre une meilleure décision concernant le traitement chirurgical endodontique ou non chirurgical endodontique prévu.

Zusammenfassung

Einleitung

Eine erfolgreiche endodontische Behandlung erfordert fundiertes Wissen über die innere Zahnmorphologie. Detaillierte anatomische Informationen sind Grundlage für das Verständnis des dreidimensionalen Wurzelkanalsystems. Sie bilden die Voraussetzung für klinisch-chirurgische oder nicht chirurgische Therapieentscheidungen. Bisher wurden in der Literatur die Morphologie und die Wurzelkanalkonfiguration von zweiten Unterkiefermolaren selten untersucht. Mit der heutzutage möglichen Mikro-Computer-Tomografie (Mikro-CT) mit 3-D-Darstellungs-Software kann das Wurzelkanalsystem detailliert untersucht werden. Das Mikro-CT gilt als non destruktive und reproduzierbare Ex-vivo-Forschungsmethode, die gegenüber konventionellen Methoden zusätzliche Informationen zu morphologischen Strukturen liefert.

Material und Methoden

Die Wurzelkanalkonfiguration und die Anzahl an Foramina sowie akzessorischen Wurzelkanälen von 93 zweiten Unterkiefermolaren wurden analysiert. Die Wurzelkanalkonfiguration und Anzahl an Hauptforamina wurden mittels eines vierstelligen Codes von koronal nach apikal beschrieben. Dabei stellen die ersten drei Ziffern das koronale, mittlere und apikale Drittel des Wurzelkanals an der koronalen Grenze des jeweiligen Drittels dar. Die vierte Ziffer wird durch einen Schrägstrich abgetrennt und gibt die Anzahl der Hauptforamina an.

Ergebnisse

Die am häufigsten beobachteten Wurzelkanalkonfigurationen in der mesialen Wurzel waren 2-2-1/1 (32,3%), 2-2-2/2 (28,0%), 1-1-1/1 (6,5%) und 2-1-1/1 (6,5%). Weitere zwölf verschiedene Wurzelkanalkonfigurationen wurden gefunden. In der distalen Wurzel war die Wurzelkanalkonfiguration 1-1-1/1 mit 81,7% die am häufigsten beobachtete. Weitere zehn unterschiedliche Wurzelkanalkonfigurationen mit einer Häufigkeit von weniger als 5% wurden in dieser Wurzel ebenso beobachtet. Man konnte Anastomosen zwischen den mesiobuccalen (MB) und mesiolingualen (ML) Kanälen in der mesialen Wurzel im koronalen (20,5%), mittleren (19,4%) und apikalen (10,8%) Drittel identifizieren. Akzessorische Wurzelkanäle wurden im koronalen (MB 15,5%, ML 12,9%, distobuccal [DB] 1,1%), mittleren (MB 7,5%, ML 10,8%, distolingual [DL] 3,3%) und apikalen Drittel (MB 19,3%, ML 16,2%, DL 10,8%) beobachtet.

Diskussion

Die Ergebnisse der vorliegenden Studie wurden mit anderen Studien der einschlägigen Literatur verglichen. Die Unter-

schiede zwischen den Ergebnissen lassen sich durch die unterschiedlichen Untersuchungsmethoden, die Bewertungsparameter und den Ursprung der verwendeten Proben erklären. In dieser Studie handelt es sich um eine ägyptische Stichprobe. In Voruntersuchungen zu dieser Studie wurde diese mit Stichproben aus Mitteleuropa verglichen. Hinsichtlich ihrer Wurzelkanalkonfiguration wurden Ähnlichkeiten beobachtet, und diese grosse Stichprobe daher zur weiteren Untersuchung ausgewählt. Zusammenfassend waren die Wurzelkanalkonfigurationen von zweiten Unterkiefermolaren in dieser Studie sehr unterschiedlich. Sie zeigten weniger morphologische Diversifikationen als erste Unterkiefermolaren. Dennoch wies das Wurzelkanalsystem der mesialen Wurzel mehr Wurzelkanalkonfigurationen, Verbindungs- und akzessorische Kanäle auf als die distale Wurzel. Das Vorkommen von akzessorischen Wurzelkanälen und Foramina sowie Anastomosen unter-

streicht die Bedeutung einer obligatorischen und gründlichen chemo-mechanischen Reinigung des Wurzelkanalsystems, vor allem in Bereichen, die nicht mechanisch präpariert werden können. Das Nichterreichen dieses Ziels würde höchstwahrscheinlich zu einer mühsamen Wiederbehandlung, zu chirurgischen Eingriffen oder sogar zu einer Zahnentfernung führen. Zur Vermeidung von iatrogenen Fehlern wird in der vorliegenden Studie daher ein Überblick der Zahnmorphologie aus einer grossen Stichprobe von zweiten Unterkiefermolaren, die durch Mikro-CT untersucht wurden, bereitgestellt. Die vorgestellten Informationen tragen zum genauen Verständnis und Wissen über die Wurzelkanalanatomie der zweiten Unterkiefermolaren bei. Sie sollen Praktikern dabei helfen, schwierige chirurgische und nicht chirurgische endodontische Behandlungsaufgaben zu bewältigen und bessere Therapieentscheidungen zu treffen.

References

- AHMED H A, ABU-BAKR N H, YAHIA N A, IBRAHIM Y E: Root and canal morphology of permanent mandibular molars in a Sudanese population. *Int Endod J* 40: 766–771 (2007)
- AMOROSO-SILVA P A, ORDINOLA-ZAPATA R, DUARTE M A H, GUTMANN J L, DEL CARPIO-PEROCHENA A, BRAMANTE C M, DE MORAES I G: Micro-computed tomographic analysis of mandibular second molars with c-shaped root canals. *J Endod* 41: 890–895 (2015)
- BARNES S A, BOWLES W R, FOK A, McCLANAHAN S B, HARRIS S P: An anatomical investigation of the mandibular second molar using micro-computed tomography. *Surg Radiol Anat* 37: 267–272 (2015)
- BRISEÑO-MARROQUÍN B, PAQUÉ F, WILLERSHAUSEN B, WOLF T G: Root canal morphology and configuration of 179 maxillary first molars by means of micro-computed tomography. An ex vivo study. *J Endod* 41: 2008–2013 (2015)
- BYSTRÖM A, SUNDBQVIST G: Bacteriologic evaluation of the efficacy of mechanical root canal instrumentation in endodontic therapy. *Scand J Dent Res* 89: 321–328 (1981)
- ÇALIŞKAN M K, PEHLIVAN Y, SEPETÇIOĞLU F, TÜRKÜN M, TUNCER S S: Root canal morphology of human permanent teeth in a Turkish population. *J Endod* 21: 200–204 (1995)
- CHANG S-W, LEE J-K, LEE Y, UM K-Y: In-depth morphological study of mesiobuccal root canal systems in maxillary first molars: review. *Restor Dent Endod* 38: 2–10 (2013)
- CLEGHORN B M, CHRISTIE W H, DONG C C S: Root and root canal morphology of the human permanent maxillary first molar: a literature review. *J Endod* 32: 813–821 (2006)
- DE DEUS Q D: Frequency, location, and direction of the lateral, secondary, and accessory canals. *J Endod* 1: 361–366 (1975)
- DOMARK J D, HATTON J F, BENISON R P, HILDEBOLT C F: An ex vivo comparison of digital radiography and cone-beam and micro computed tomography in the detection of the number of canals in the mesiobuccal roots of maxillary molars. *J Endod* 39: 901–905 (2013)
- GAO Y, FAN B, CHEUNG G S P, GUTMANN J L, FAN M: C-shaped canal system in mandibular second molars, part IV: 3-D morphological analysis and transverse measurement. *J Endod* 32: 1062–1065 (2006)
- GULABIVALA K, AUNG T H, ALAVI A, NG Y L: Root and canal morphology of Burmese mandibular molars. *Int Endod J* 34: 359–370 (2001)
- JORDAN R E, ABRAMS L, KRAUS B S: Kraus' dental anatomy and occlusion. Mosby year book, St. Louis (1992)
- MARROQUÍN B B, EL-SAYED M A A, WILLERSHAUSEN-ZÖNNCHEN B: Morphology of the physiological foramen: I. Maxillary and mandibular molars. *J Endod* 30: 321–328 (2004)
- MIN Y, FAN B, CHEUNG G S P, GUTMANN J L, FAN M: C-shaped canal system in mandibular second molars, Part III: The morphology of the pulp chamber floor. *J Endod* 32: 1155–1159 (2006)
- NIELSEN R B, ALYASSIN A M, PETERS D D, CARNES D L, LANCASTER J: Microcomputed tomography: an advanced system for detailed endodontic research. *J Endod* 21: 561–8 (1995)
- PAQUÉ F, GANAHL D, PETERS O A: Effects of root canal preparation on apical geometry assessed by micro-computed tomography. *J Endod* 35: 1056–1059 (2009)
- PAQUÉ F, PETERS O A: Micro-computed tomography evaluation of the preparation of long oval root canals in mandibular molars with the self-adjusting file. *J Endod* 37: 517–521 (2011)
- PAQUÉ F, AL-JADAA A, KFIR A: Hard-tissue debris accumulation created by conventional rotary versus self-adjusting file instrumentation in mesial root canal systems of mandibular molars. *Int Endod J* 45: 413–418 (2012)
- PARK J W, LEE J K, HA B H, CHOI J H, PERINPANAYAGAM H: Three-dimensional analysis of maxillary first molar mesiobuccal root canal configuration and curvature using micro-computed tomography. *Oral Surg Oral Med Oral Pathol Oral Radiol Endod* 108: 437–442 (2009)
- PINEDA F, KUTTLER Y: Mesiodistal and buccolingual roentgenographic investigation of 7,275 root canals. *Oral Surg Oral Med Oral Pathol* 33: 101–110 (1972)
- PLOTINO G, GRANDE N M, PECCI R, BEDINI R, PAMEJER C H, SOMMA F: Three-dimensional imaging using microcomputed tomography for studying tooth macromorphology. *J Am Dent Assoc* 137: 1555–1561 (2006)
- RHODES J S, FORD T R, LYNCH J A, LIEPINS P J, CURTIS R V: Micro-computed tomography: a new tool for experimental endodontology. *Int Endod J* 32: 165–170 (1999)
- RWENYONYI C M, KUTESA A, MUWAZI L M, BUWEMBO W: Root and canal morphology of mandibular first and second permanent molar teeth in a Ugandan population. *Odontology* 97: 92–96 (2009)
- SCHILDER H: Filling root canals in three dimensions. *Dent Clin North Am* 723–744 (1967)
- SCHILDER H: Cleaning and shaping the root canal. *Dent Clin North Am* 18: 269–296 (1974)
- SERT S, BAYIRLI G S: Evaluation of the root canal configurations of the mandibular and maxillary permanent teeth by gender in the Turkish population. *J Endod* 30: 391–398 (2004)
- SHEMESH A, LEVIN A, KATZENELL V, ITZHAK J B, LEVINSON O, AVRAHAM Z, SOLOMONOV M: C-shaped canals – prevalence and root canal configuration by cone beam computed tomography evaluation in first and second mandibular molars – a cross-sectional study. *Clin Oral Investig* (2016) [Epub ahead of print]
- VERTUCCI F J: Root canal anatomy of the human permanent teeth. *Oral Surg Oral Med Oral Pathol* 58: 589–599 (1984)
- WEINE F S, PASIEWICZ R A, RICE R T: Canal configuration of the mandibular second molar using a clinically oriented in vitro method. *J Endod* 14: 207–213 (1988)
- WOLF T G, PAQUÉ F, ZELLER M, WILLERSHAUSEN B, BRISEÑO-MARROQUÍN B: Root canal morphology and configuration of 118 mandibular first molars by means of micro-computed tomography: an ex vivo study. *J Endod* 42: 610–614 (2016)
- WOLF T G, PAQUÉ F, WOOP A C, WILLERSHAUSEN B, BRISEÑO-MARROQUÍN B: Root canal morphology and configuration of 123 maxillary second molars by means of micro-CT. *Int J Oral Sci* 9: 33–37 (2017)